

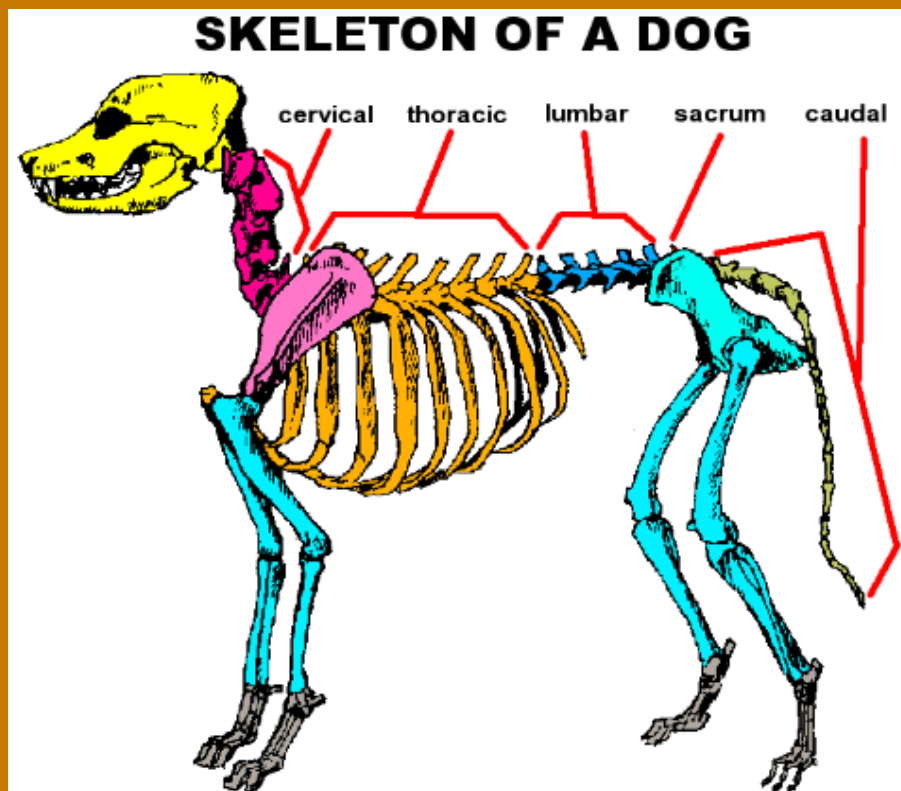


Animal Working Group Newsletter

September 2023

Canine Spinal Anatomy

- The canine spinal column is made up of 7 cervical vertebrae, 13 thoracic, 7 lumbar, 3 sacral, and approximately 20 coccygeal vertebrae.
- Intervertebral discs are located from C2 to L7/S1.
- The sacrum is fused by 2 years of age and does not obtain any discs.
- The tail does have intervertebral discs, but are small and thought to have no clinical significance.



If you have a topic that you would like to be covered, let us know!

Also, if you have a pet that you would like to show off, send your pictures to drgraydc@gmail.com and we will try to incorporate them in future newsletters!